

CORRECTION

Open Access



# Correction: Attenuation of pathogenesis of *Eimeria stiedae* sporulated oocysts using Egyptian alginate propolis nanoparticles

Ahmed G. Hegazi<sup>1</sup>, Eman E. El Shanawany<sup>2\*</sup>, Asmaa S. El-Houssiny<sup>3</sup>, Soad E. Hassan<sup>2</sup>, Hassan M. Desouky<sup>4</sup>, T. M. El-Metenawy<sup>2</sup> and Eman H. Abdel-Rahman<sup>2</sup>

## Correction: BMC Vet Res 19, 127 (2023)

<https://doi.org/10.1186/s12917-023-03689-y>

Following publication of the original article [1], the authors identified the following errors in the published version.

- There are errors during the production process in the result section of this article such as Fig. 7 was incorrectly cited and replaced by Fig. 8. Also, citation of Fig. 7F and G in the text was missed so there are paragraph need to be added after the end of paragraph which cited as Fig. 7E. The paragraph that needs to be added is "The hepatic parenchyma showed severe degenerative and necrotic changes of hepatocytes

associated with multiple small scattered areas of hemorrhages, in addition to extensive intercellular fibrosis and mononuclear cell infiltration were seen (Fig. 7F). There was centrilobular and perilobular fibrous C.T. proliferation. Moreover, marked dilatation and congestion of the central vein and hepatic sinusoids associated with the hemorrhagic area were observed (Fig. 7G)". The correct figure is given below.

Published online: 30 August 2023

## Reference

1. Hegazi AG, Shanawany EEE, El-Houssiny AS, et al. Attenuation of pathogenesis of *Eimeria stiedae* sporulated oocysts using Egyptian alginate propolis nanoparticles. *BMC Vet Res.* 2023;19:127. <https://doi.org/10.1186/s12917-023-03689-y>.

The original article can be found online at <https://doi.org/10.1186/s12917-023-03689-y>.

\*Correspondence:

Eman E. El Shanawany  
ee.el-shanawany@nrc.sci.eg

<sup>1</sup> Zoonotic Diseases Department, Veterinary Research Institute, National Research Centre, Dokki-Giza, Egypt

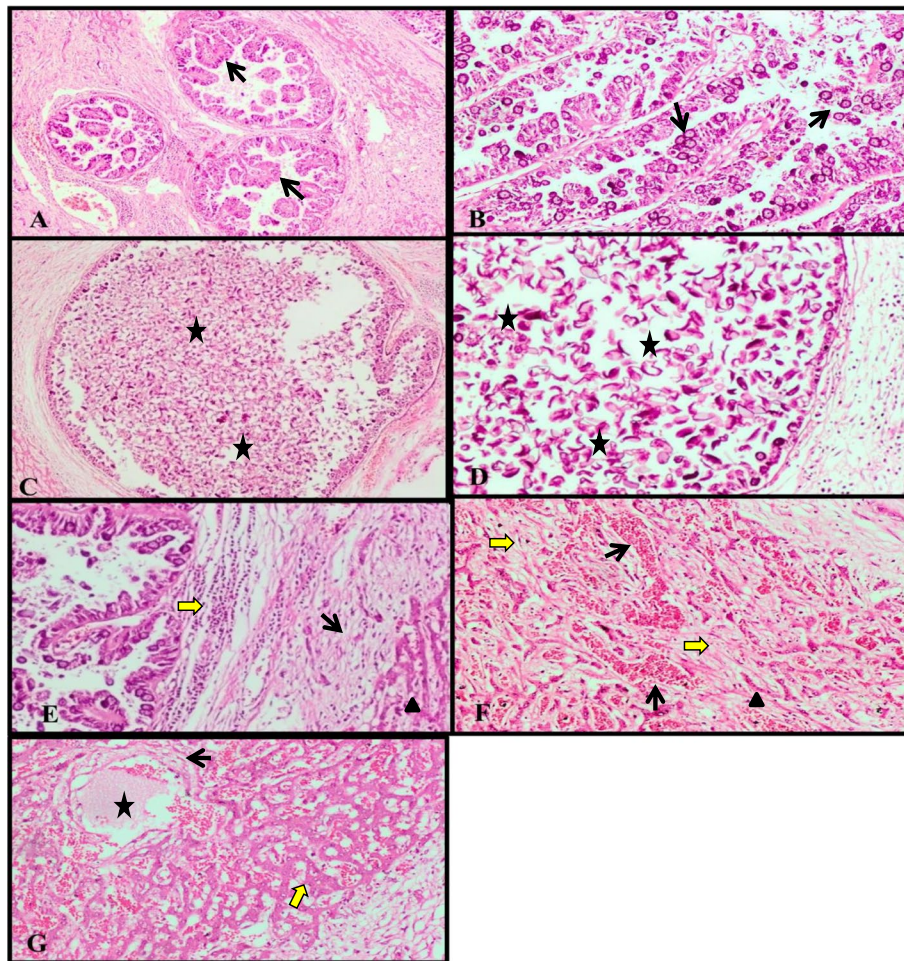
<sup>2</sup> Parasitology and Animal Diseases Department, Veterinary Research Institute, National Research Centre, Dokki, Giza, Egypt

<sup>3</sup> Microwave Physics and Dielectric Department, National Research Centre, Dokki-Giza, Egypt

<sup>4</sup> Animal Reproduction and Artificial Insemination Department, National Research Centre, Dokki-Giza, Egypt



© The Author(s) 2023. **Open Access** This article is licensed under a Creative Commons Attribution 4.0 International License, which permits use, sharing, adaptation, distribution and reproduction in any medium or format, as long as you give appropriate credit to the original author(s) and the source, provide a link to the Creative Commons licence, and indicate if changes were made. The images or other third party material in this article are included in the article's Creative Commons licence, unless indicated otherwise in a credit line to the material. If material is not included in the article's Creative Commons licence and your intended use is not permitted by statutory regulation or exceeds the permitted use, you will need to obtain permission directly from the copyright holder. To view a copy of this licence, visit <http://creativecommons.org/licenses/by/4.0/>. The Creative Commons Public Domain Dedication waiver (<http://creativecommons.org/publicdomain/zero/1.0/>) applies to the data made available in this article, unless otherwise stated in a credit line to the data.



**Fig. 7** Liver of rabbit infected with *E. steadiei* non-treated sporulated oocysts **A** showing proliferation, marked enlargement of bile ducts, extensive hyperplasia of the biliary epithelium forming multiple long papillary projections (arrows) (H&E, X40). **B** Showing invasion of the papillomatous proliferation of biliary epithelium with numerous and various developmental stages of the coccidian parasite (arrows) (H&E, X100). **C** Showing the cystic formation of the bile duct associated with the presence of massive numbers of oval non-sporulated oocysts (stars), and cellular debris within the lumen. (H&E, X100). **D** Higher magnification of figure C (H&E, X200). **E** Showing extensive peribiliary fibrosis (black arrow) associated with infiltration of mononuclear cells (yellow arrow), in addition to necrosis of hepatocytes (arrow head) (H&E, X100). **F** Showing multiple small scattered areas of hemorrhages in hepatic parenchyma associated with fibrosis and severe degenerative and necrotic changes of hepatocytes (yellow arrow) (H&E, X100). **G** Showing high dilatation and congestion of central vein (star) and sinusoids associated with necrosis of endothelial cells lining and centrilobular fibrous C.T. proliferation (black arrow) in addition to necrosis of hepatic cells (yellow arrow) and lymphocytic cell infiltration. (H&E, X100)